



Contents lists available at <https://americanjournalofcasereports.com/>

American Journal of Case Reports and Clinical Images



81-Year-Old Male Diagnosed Acute Exacerbation of Chronic Obstructive Pulmonary Disease (AECOPD) With Hypercapnic Respiratory Failure (T2RF): A Case Report

¹Damini Kharb, ²Shipra Omar, ²Dr.Kanishk Kala, ¹Shagufta Jawaid, ¹Krishan Kant Kushwaha

¹Doctor of Pharmacy, Department of Pharmacy Practice, School of Pharmaceutical Sciences, Shri Guru Ram Rai University, Shri Mahant Indresh Hospital Dehradun-248001, Uttarakhand, India.

²Assistant Professor, Faculty of Pharmacy Practice, School of Pharmaceutical Sciences, Shri Guru Ram Rai University, Shri Mahant Indresh Hospital Dehradun-248001, Uttarakhand, India.



ARTICLE INFO

Article history:

Received: 25-05-2024

Revised: 28-06-2024

Accepted: 01-07-2024

Published: 04-07-2024

KEYWORDS:

Bronchitis,

Emphysema,

Non-Invasive ventilator,

Hyperinflation,

V/Q mismatch.

ABSTRACT

Small airway disease and lung parenchymal deterioration are the causes of Chronic Obstructive Pulmonary Disease (COPD), an irreversible restriction of airflow. Based on identifiable clinical and ABG findings and evidence of elevated pulmonary artery pressure titers against pedal edema in ECHO, the diagnosis of AECOPD with T2RF was determined. In this case, a male patient with AECOPD-induced Type 2 respiratory failure (T2RF) with pedal edema was admitted to the respiratory medicine unit at SMIH Dehradun. This was a rare incident of PAH. The results of the ABG analysis and ECG investigations revealed hypercapnic respiratory failure and acute myocardial infarction with ST elevation. A non-invasive ventilator (BiPAP) was used to stabilize the patient. **Copyrights**

© 2024, Damini Kharb, et al. This article is licensed under the Creative Commons Attribution-Non-Commercial-4.0-International-License-(CCBY-NC) (<https://americanjournalofcasereports.com/blogpage/copyright-policy>). Usage and distribution for commercial purposes require written permission.

INTRODUCTION

Chronic Obstructive Pulmonary Disease (COPD) is an eternity, incurable airflow restriction spurred on by small airway disease and lung parenchymal destruction [1]. Acute Exacerbation of Chronic Obstructive Pulmonary Disease (AECOPD) is the term for an abrupt deterioration of COPD symptoms [2]. It is characterized by a persistent blockage of airflow spurred on by lung injury, often from smoking or being around pollution [3]. Patients have difficulty evacuating their lungs completely when they exhale, which causes air to become lodged and cause hyperinflation [4]. Hypercapnia results from the lungs' incapacity to adequately expel CO₂ [5]. The lungs lose their elasticity due to COPD, and due to being obliged to work harder to breathe, the diaphragm and other breathing muscles inevitably tire out [6]. Tachypnoea is the body's attempt at compensating, but it frequently falls short of maintaining proper breathing, leading to hypoventilation and hypercapnia [7].

Case Presentation:

An 81-year-old male patient presented to the Pulmonary medicine ward with chief complaints of cough with sputum on & off, fever for 4 days, and generalized weakness followed by pedal edema. The patient had a history of shortness of breath for the last 5-7 days. The patient had a social history of smoking (ex-smoker) till 2010 and had a family history of Shortness of Breath (SOB). With the following complaints patient was admitted to the

pulmonary medicine department. The patient had following investigations of CBC, FBS, CMP, ABG, C-XR and ECG.

Table 1: Complete Blood Count and Comprehensive Metabolic Panel. Fasting Blood Sugar, Vitamin D Total (25-OH D3).

Complete Blood Count	Comprehensive Metabolic Panel
Haemoglobin (HB): 14.6 (13.0 - 17.0 GM/DL)	SGPT (ALTV), SERUM: 78 (4 - 50 U/L)
Total Leukocyte Count (TLC): 12400 (4000 - 11000 / cumm)	Alkaline Phosphatase, Serum: 129 (38 - 126 U/L)
Differential Leucocyte Count (DLC) Neutrophils: 88 (44.0 - 68.0%) Lymphocytes: 04 (25.0 - 48.0%) Eosinophil: 00 (1.0 - 6.0%)	Sodium: 134 (137 - 145 mmol/L) Potassium: 5.7 (3.5 - 5.1 mmol/L) Chloride: 97 (98 - 107 mmol/L)
MCHC: 29.8 (31.5 - 34.5 gm/dl)	Albumin, Serum: 3.20 (3.50 - 5.00 gm/ dL)
Platelet Count: 85 (150 - 400 10 ³ /uL)	Urea-Serum: 52 (19 - 43 mg/dL)
RDW: 15.70 (11.60 - 14.10 CV%)	Cholesterol-Total, Serum: 105 (150 - 200 mg/dL)
	Vitamin D Total (25-OH D3):12.5 (30.0 - 100.0 ng/ml)

* Corresponding author.

Damini Kharb, Doctor of Pharmacy, Department of Pharmacy Practice, School of Pharmaceutical Sciences, Shri Guru Ram Rai University, Shri Mahant Indresh Hospital Dehradun-248001, Uttarakhand, India.

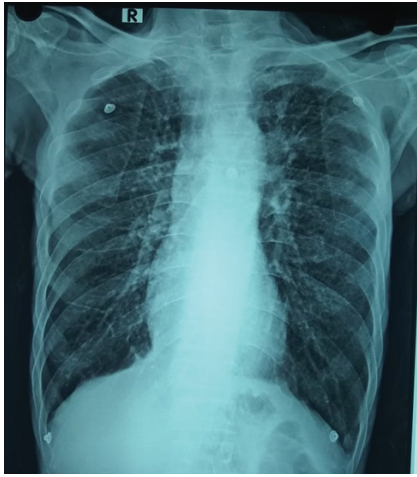

Figure 1: X-Ray-Chest AP-view Illustrates Bilateral Hyperinflated Lungs.

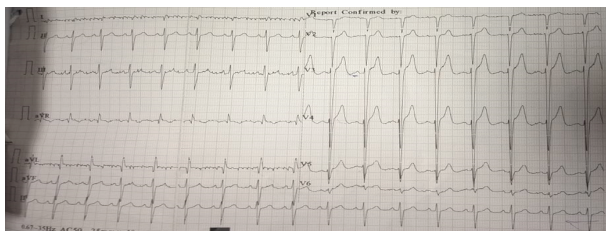


Figure 2: ECG (Sinus rhythm, left anterior hemiblock, suspect antero-septal myocardial infarction, suspect lateral Myocardial infarction with slight ST elevation).

Table 2: ABG (Arterial Blood Gas) Illustrated Metabolic Alkalosis compensated by Respiratory Acidosis.

Components	24-Sep	25-Sep	26-Sep	27-Sep	28-Sep	29-Sep	30-Sep	Normal Range
pH	7.39	7.48	7.42	7.44	7.46	7.53	7.43	7.35-7.45
pCO ₂	66	53	68	58	57	60	59	35-45mmHg
pO ₂	34	54	88	47	44	61	42	60-100mmHg
HCO ₃ ⁻	40	39.5	44.1	39.4	40.5	50.1	39.2	22-26mmol/L
HCO ₃ std.	32.7	35.2	36.9	34.3	35.4	42.7	33.8	
BE	11.4	13.5	15.4	12.5	14	22.9	12.1	
SO ₂ C	65	90	97	84	82	94	79	
Hct	54	47	52	48	45	49	48	

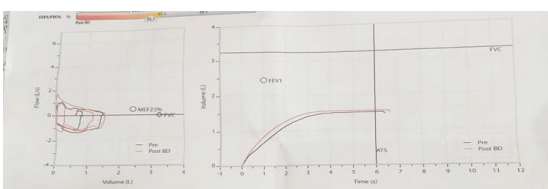
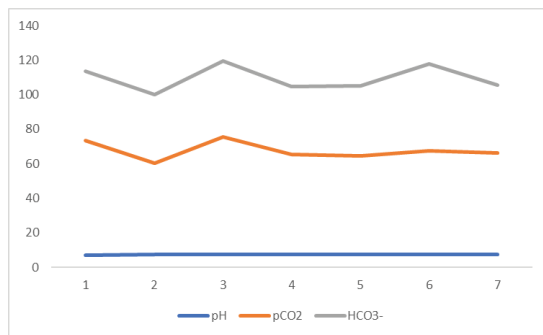


Figure 3: Spirometry Illustrates Severe Obstruction with Poor Bronchodilator Response.

Table 3: Spirometry before and after Bronchodilator Response. (Bronchodilator "Salbutamol 200 mcg").

	Meas.	Normal Range	Pred	%Pred	z-score	Meas.	Change	%Change	%Pred	Z-score
FVC	1.54	2.38-4.10	3.24	47	-3.31	1.59	0.06	4	49	-3.20
FEV1	0.70	1.69-3.15	2.45	29	-3.52	0.89	0.19	27	36	-3.20
FEV1/FVC%	45.4	62.5-88.5	76.1	60	-3.44	55.7	10.2	23	73	-2.40
FEF25-75%	0.48	0.69-3.46	1.81	27	-2.07	0.58	0.10	20	32	-1.86
MEF25%	0.39	0.16-1.23	0.45	86	-0.24	0.39	0.00	1	87	-0.23
FEV1/VC max%	45.4	62.5-88.5	76.1	60	-3.44	55.7	10.2	23	73	-2.40

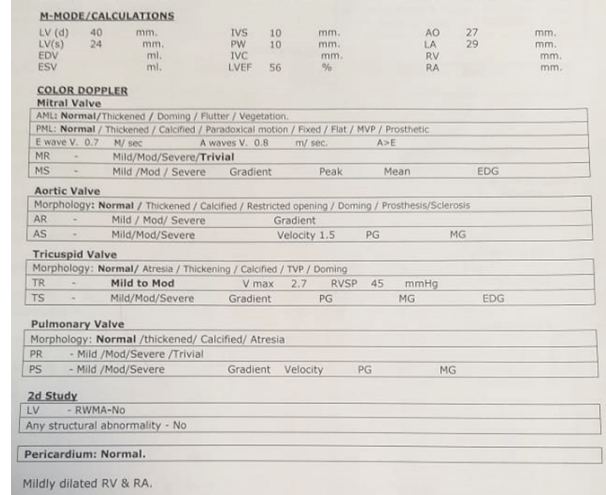


Figure 4: Patient ECHO illustrates (Grade 1 Diastolic Dysfunction with Normal LV Function 56%, Mild to Moderate, Moderate Pulmonary Arterial Hypertension).

Table 4: Medication Treatment Chart.

Medication	Dose	Route	Frequency
INJ.AUGMENTIN	1.2gm	IV	TDS
INJ.AZEE	500mg	IV	OD
INJ.PANTOP	40mg	IV	OD
TAB.NAC	600mg	ORAL	TDS
TAB.DOXOLLIN	200mg	ORAL	BD
INJ. SOLUMEDROL	40mg	IV	TDS
INJ. CLEXANE	0.4ml	IV	OD
INJ. LASIX	10mg	IV	BD
K-Bind Sachet	15g	oral	TDS
INJ. CAGLUCONATE	10%	IV	STAT
NEB.DUOLIN	3ml	INHALER	QID
NEB. BUDECORT	2ml	INHALER	BD

- Patient urine Examination, prothrombin time, and international normalized ratio were normal.
- Patient TNI was found to be 0.02ng/ml.
- The patient's lung sound illustrates bilateral decreased exertion with unusual wheeze.
- Patient's Chest Xray Illustrates Prominent Broncho vascular markings with reticulations are noted in bilateral lung fields. Bilateral lung fields are hyperinflated with tubular heart and flattening of bilateral domes of diaphragm-s/o COPD changes. Tenting of the right dome of the diaphragm is seen. Degenerative changes are seen in the form of multilevel marginal osteophytes. The left CP angle is indistinct.
- D-Dimer, Quantitative: CH 767 (0 - 255 ng/ml).

Discussion and Conclusion:

AECOPD is the term for a sudden deterioration of COPD symptoms in patients, usually characterized by increased coughing, sputum production, dyspnoea, and occasionally fever. Pedal edema complicates matters further when it occurs during AECOPD since it may be a sign of cor pulmonale, a condition in which chronic lung illness causes the right side of the heart to fail. Pulmonary hypertension may result from prolonged hypoxia and airflow restriction brought on by COPD. The right side of the heart must work harder to pump blood through the lungs due to the strain the increased pressure in the pulmonary arteries puts on it. Cor pulmonale, or right heart failure, may result from this over time. Peripheral edema, especially pedal edema, is a possible manifestation of the ensuing fluid overload.

AECOPD can be effectively managed with BiPAP, particularly in individuals who have hypercapnic respiratory failure. When someone presents with pedal edema, which frequently indicates the existence of cor pulmonale or right heart failure, its role becomes even more crucial. In addition to easing respiratory symptoms, BiPAP lessens cardiac strain and may help prevent fluid retention and edema by enhancing ventilation, oxygenation, and respiratory muscle exhaustion. To prevent cardiovascular system problems, however, close observation is necessary, particularly in individuals with severe heart failure.

Since the patient had a history of smoking, type 2RF was diagnosed, resulting in a bilaterally enlarged lung field with tubular lungs. Severe obstruction, mild ST elevation, lateral and anteroseptal MI left anterior hemiblock, and Grade 1 diastolic dysfunction are the results of his findings. Moderate PAH causes right ventricle failure, which is followed by the backflow of blood towards the veins, which causes pedal edema and raises blood pressure, which the body initially compensates for. As the medication therapy was given the the patient was resulting in Hypokalaemia which resulted in respiratory distress followed by severe conditioning of the patient. Intravenous calcium gluconate was used to treat the patient's hypokalaemia, a significant sign of respiratory failure. As clinical pharmacist

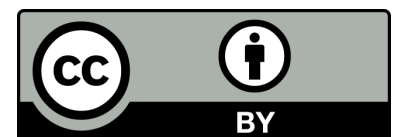
Intervention, we should closely monitor patients' vitals and electrolyte balance and give dietary and lifestyle recommendations, Close monitoring and individualized treatment strategies can improve patient outcomes and reduce hospitalizations, but the prognosis tends to be worse in patients presenting with both AECOPD and pedal edema. The patient received conservative care to improve the quality of life.

Conflict of interest: None

Ethical Consideration: Not Required.

REFERENCES

1. Muruganandan S. Optimising care of individuals with malignant pleural effusion. 2021.
2. Liu L, Chen Y, He G, Lin B, Zhu Z, Wei R, et al. Exploring the impact of OSA on short-term survival in patients with AECOPD admitted to the ICU. *Plos one*. 2024;19(4):e0301646.
3. Ong KC. Pulmonary Emphysema-Recent Updates: Recent Updates: BoD-Books on Demand; 2024.
4. Camp PG, Reid WD, Chung F, Hill K. Anatomy and Physiology of the Respiratory and Cardiovascular Systems. *Cardiopulmonary Physical Therapy: Routledge*; 2024. p. 25-52.
5. Wetzel JL. Individuals with Ventilatory Pump Disorders. *Clinical Exercise Pathophysiology for Physical Therapy: Routledge*; 2024. p. 283-317.
6. Jackman R. Dynamic hyperinflation and exertional dyspnea in COPD patients pre-and post-lung transplant: University of British Columbia; 2024.
7. Bedenice D. Section VIII Nonpulmonary Disease Processes Manifesting as Respiratory Disease. *Equine Neonatal Medicine*. 2024:216.



Submit your manuscript to the

American Journal of Case Reports and Clinical Images
CODEN: USA

and benefit from:

- Convenient online submission
- Rigorous peer review
- Immediate publication on acceptance
- Open access: articles freely available online
- High visibility within the field
- Retaining the copyright to your article

Submit your manuscript at

<https://americanjournalofcasereports.com/>
&

wjcasereports@gmail.com; submission@americanjournalofcasereports.com